

UT Southwestern Department of Radiology

Ultrasound – Parathyroid Gland Evaluation

PURPOSE:

To identify enlarged parathyroid glands.

SCOPE:

Applies to all US Abdomen Complete studies performed in Imaging Services / Radiology

INDICATIONS:

- Signs or symptoms associated with hyperparathyroidism
- Abnormal lab values (increased parathyroid hormone, hypercalcemia)
- Abnormal findings on other imaging studies
- Follow up known parathyroid abnormalities
- Evaluate for recurrent disease in the setting of previous parathyroid surgery or ablation

CONTRAINDICATIONS:

- No absolute contraindications

EQUIPMENT:

Linear array transducer with a frequency range of 9-18 MHz or greater that allows for appropriate penetration and resolution depending on patient's body habitus

PATIENT PREPARATION:

- None

EXAMINATION:

GENERAL GUIDELINES:

A complete examination includes the tissues about the thyroid gland in the anticipated locations of the parathyroid glands (superior, posterior or inferior to the thyroid lobes extending to the thoracic inlet). Include potential ectopic location in the region of the carotid bulbs and sternal notch.

If there is no formal thyroid ultrasound at our institution in the past year, then a full thyroid sonogram should also be performed (see protocol "US Thyroid" for details).

EXAM INITIATION:

- Introduce yourself to the patient
- Verify patient identity using patient name and DOB
- Explain test
- Obtain patient history including symptoms. Enter and store data page.
- Place patient in supine position with the neck extended. A pillow/towel under the shoulders may facilitate maximum neck extension.

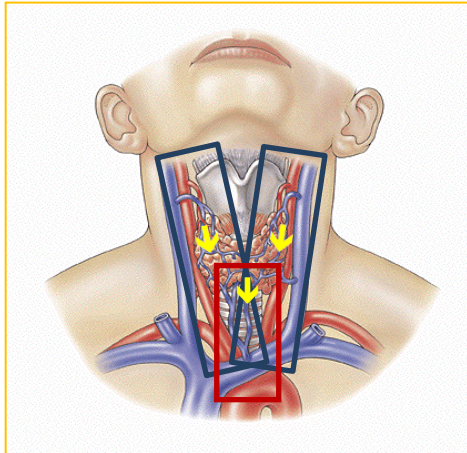
TECHNICAL CONSIDERATIONS:

- Review any prior imaging including ultrasound and nuclear medicine sestamibi scans in particular, making note of abnormalities or other findings requiring further evaluation.
- If there is no formal thyroid ultrasound at our institution in the past year, then a full thyroid sonogram should be performed in conjunction to the parathyroid evaluation. See US Thyroid Protocol.
- The soft tissues surrounding the thyroid gland and the central compartment of the anterior neck should be surveyed from the carotid arteries to the midline (longitudinal) and from the carotid bifurcation to the thoracic inlet (transverse) bilaterally (see Appendix).
- Take care to adjust depth and focus to satisfactorily image the tissues deep to the thyroid gland. Imaging with the head turned to the opposite direction may aid in “uncovering” parathyroid glands located in the tracheoesophageal groove.
- The upper mediastinum may be imaged by angling under the sternum from the sternal notch.
- Normal parathyroid glands are not seen by ultrasound. Abnormal parathyroid glands are enlarged, typically hypoechoic soft tissue nodules, usually posterior or inferior to the thyroid gland, and may exhibit a dominant feeding vessel (see Appendix).
- In most cases (80%) there is only one abnormal parathyroid, but there may be multiple, especially in the setting of tertiary hyperparathyroidism (multiglandular disease).
- Suspected parathyroid glands should be documented with size measurements in 3 orthogonal planes and without and with color Doppler. Relationship to the thyroid gland should also be noted.

DOCUMENTATION:

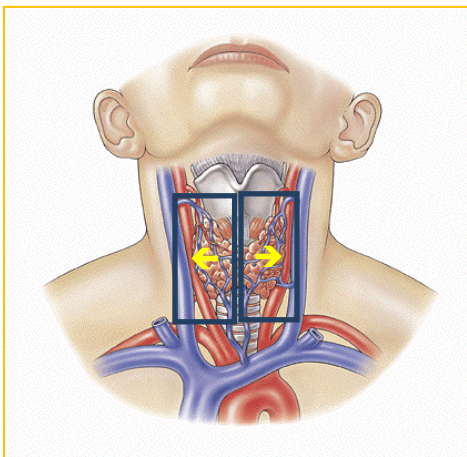
- Thyroid Gland
 - If there is no formal thyroid ultrasound at our institution in the past year, then a full thyroid sonogram should be performed in conjunction to the parathyroid evaluation. See US Thyroid protocol for details.
- Anterior Neck, Central Compartment
 - Grayscale
 - Longitudinal and transverse images focused on the soft tissues superior, posterior and inferior to each thyroid lobe (see Appendix).
 - Longitudinal and transverse images of the central compartment (Level VI) from the carotid bifurcation to thoracic inlet (see Appendix).
 - Cine Sweeps targeted to the deep (retro-thyroid) soft tissues:

Central Neck



Lateral central neck
Superior border: Submandibular gland
Inferior border: Clavicle

Midline central neck
Superior border: Thyroid isthmus
Inferior border: Manubrium



Superior border: Carotid Bulb region
Lateral border: Carotid/Jugular Complex
Medial border: Tracheal rings

- If a focal extrathyroidal soft tissue abnormality is identified, representative grayscale images without and with 3 orthogonal measurements and without and with color Doppler should be obtained.
- Data page(s)
 - Use Imorgon diagram to annotate thyroid nodules and abnormal lymph nodes (if applicable), their sizes, and suspicious features. (see Thyroid Nodule Imaging Cheat Sheet below for appropriate annotations).
 - Annotate location of any visualized parathyroid(s) on diagram.

PROCESSING:

- Review examination images and data
- Export all images to PACS
- Confirm data in Imorgon
- Document relevant history and any study limitations

REFERENCES:

ACR-AIUM Practice Guideline (Revised 2007)

ATA Guidelines (Revised 2015)

Devic Z et al. The elusive parathyroid adenoma: techniques for detection. Ultrasound Quarterly 2013, 29(3):179-87.

REVISION HISTORY:

SUBMITTED BY:	David T. Fetzer, MD	Title	Medical Director
APPROVED BY:	David T. Fetzer, MD	Title	Medical Director
APPROVAL DATE:			
REVIEW DATE(S):	09-24-2018		Lori Watumull, mD
REVISION DATE(S):	09-24-2018	Brief Summary	Minor edits for clarification

APPENDIX:

CERVICAL LYMPH NODE ANATOMIC LEVEL CLASSIFICATION

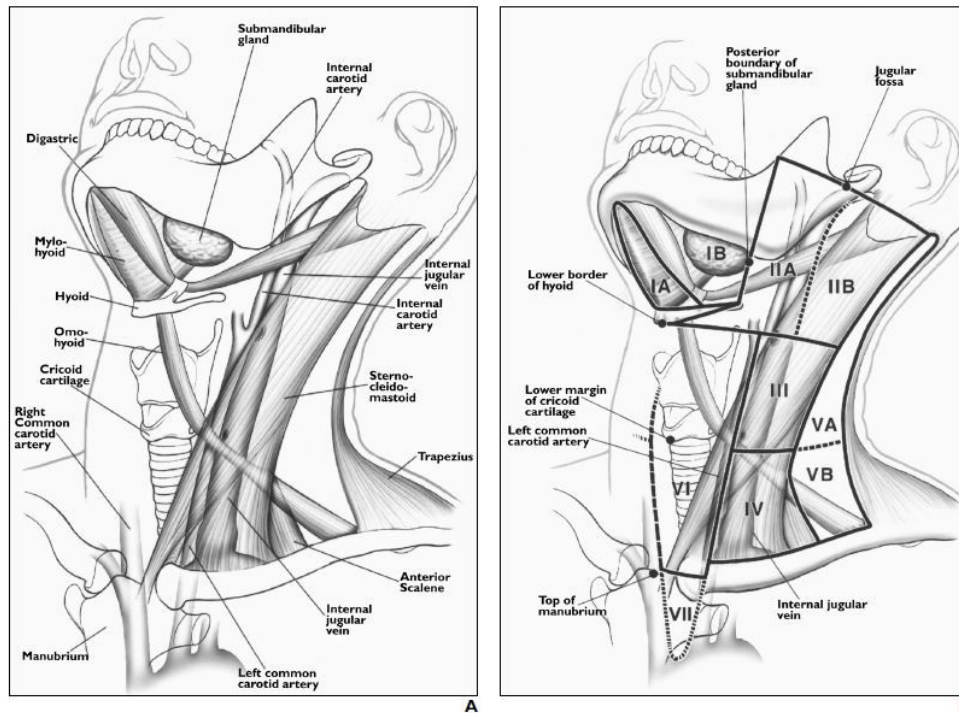
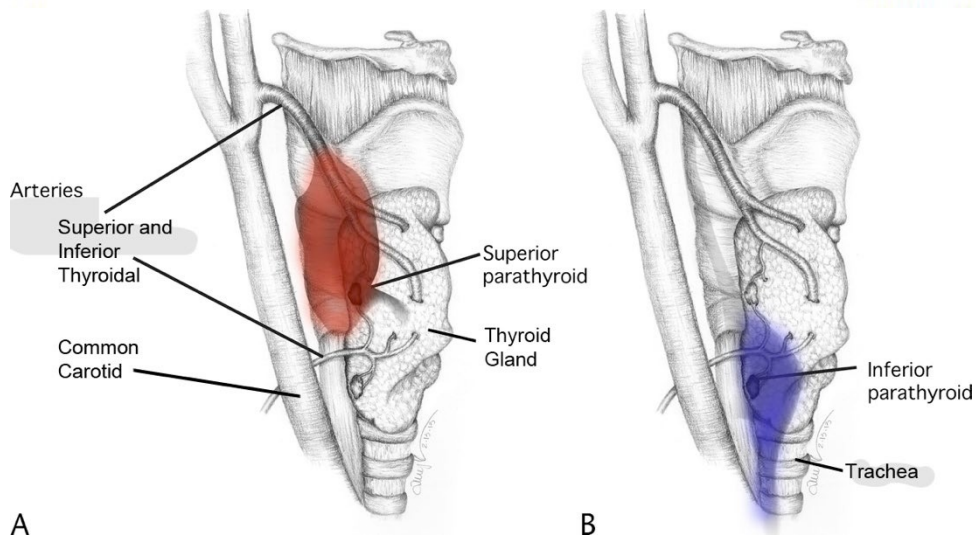


Fig. 1.—Neck as seen from left anterior view.
A. Drawing shows anatomy pertinent to nodal classification.
B. Drawing shows specific margins of anatomy seen in **A** that relate to definitions of classification levels. Note that line of separation between levels I and II is posterior margin of submandibular gland. Separation between levels II and III and level V is posterior edge of sternocleidomastoid muscle. Line of separation between levels IV and V is oblique line extending from posterior edge of sternocleidomastoid muscle to posterior edge of anterior scalene muscle. Posterior edge of internal jugular vein separates level IIA and IIB nodes. Carotid arteries separate levels III and IV from level VI. Top of manubrium separates levels VI and VII. (Reprinted with permission from [16])

838

AJR:174, March 2000



Drawing shows potential locations of parathyroid adenomas. The superior parathyroid gland (A, region in red) is typically posterior to the mid thyroid gland, while the inferior (B, region in blue) is typically posterior and inferior to the thyroid lobe. Modified from Ultrasound Quarterly, 2013.

SONOGRAPHIC APPEARANCE OF PARATHYROID ADENOMA

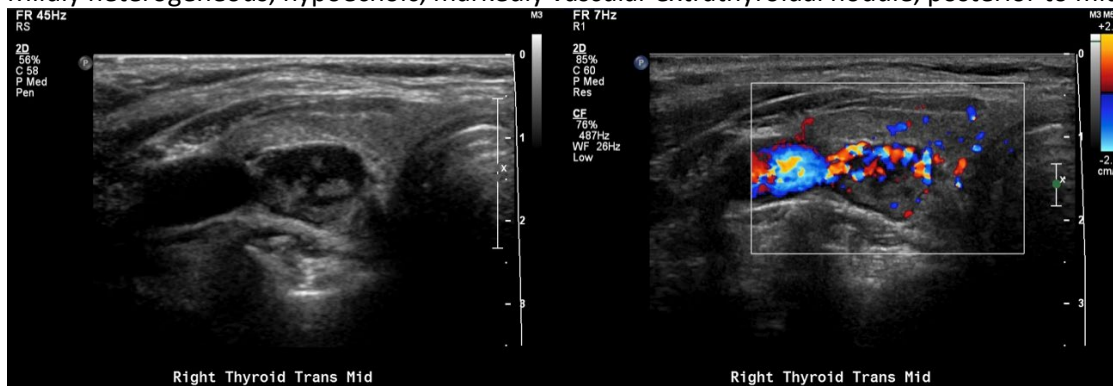
Normal parathyroid glands are not seen by ultrasound. Abnormal parathyroid glands are:

- Typically hypoechoic soft tissue nodules; may be heterogeneous or have internal cystic components
- Usually posterior or inferior to the thyroid gland, but may be superior to gland or ectopic
- Exhibit a dominant “splitting” feeding vessel

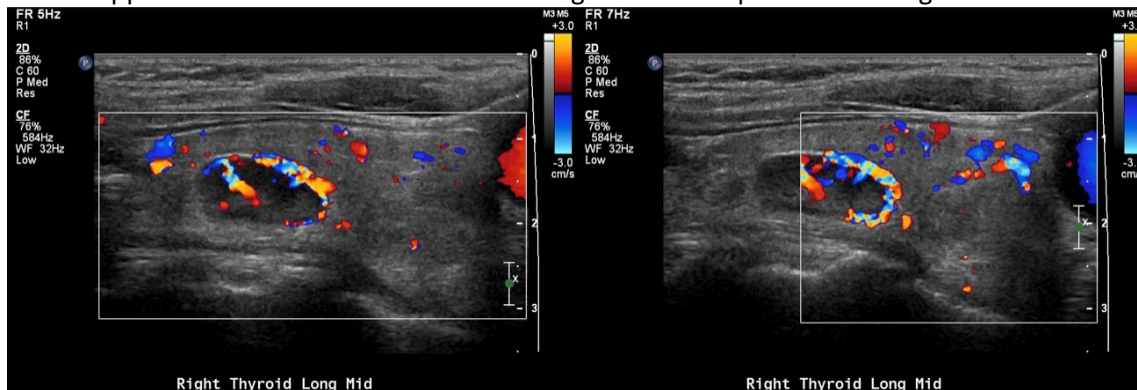
Suspected parathyroid glands should be documented with size measurements in 3 orthogonal planes and without and with color Doppler. Relation to the thyroid gland should also be noted.

EXAMPLE 1:

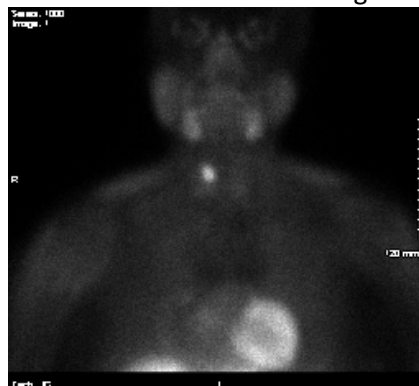Mildly heterogeneous, hypoechoic, markedly vascular extrathyroidal nodule, posterior to mid lobe



Color Doppler demonstrates a dominant feeding vessel that splits at the margin of the nodule

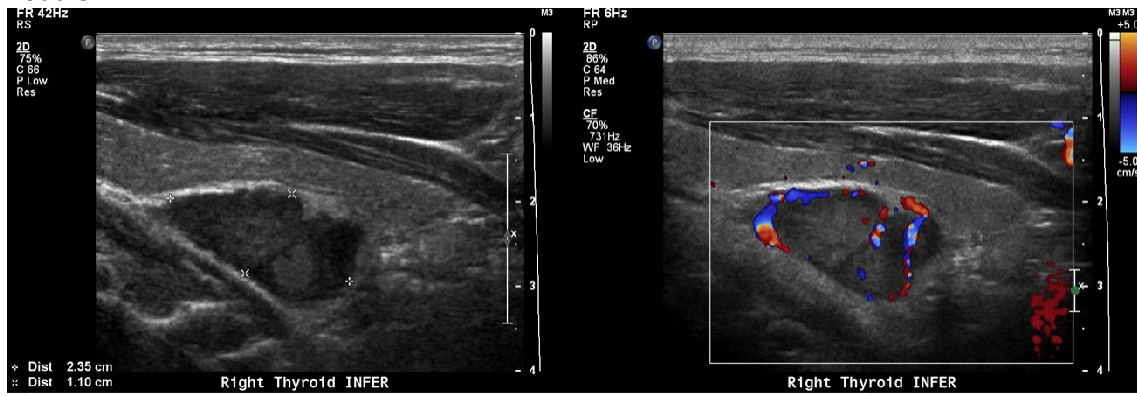

Nuclear Medicine Sestimibi scan reveals a “hot” nodule in the right neck, corresponding to this nodule.



EXAMPLE 2:

Mildly heterogeneous, hypoechoic, extrathyroidal nodule, posterior to the right lower pole. Color Doppler demonstrates several feeding vessels and a dominant splitting vessel at the margin of the nodule.



Nuclear Medicine Sestimibi scan reveals a “hot” nodule in the right neck, corresponding to this nodule.

